Distal tibia

The role of CT in diagnostics and preoperative planning

Søren Kold
Aarhus University Hospital

DANSK ORTOPÆDISK TRAUMESELSKAB

Why preoperative CT ?

- Occult intra-articular fracture

- Preoperative planning

Why not preoperative CT ?

- Iatrogenic risk of cancer ??

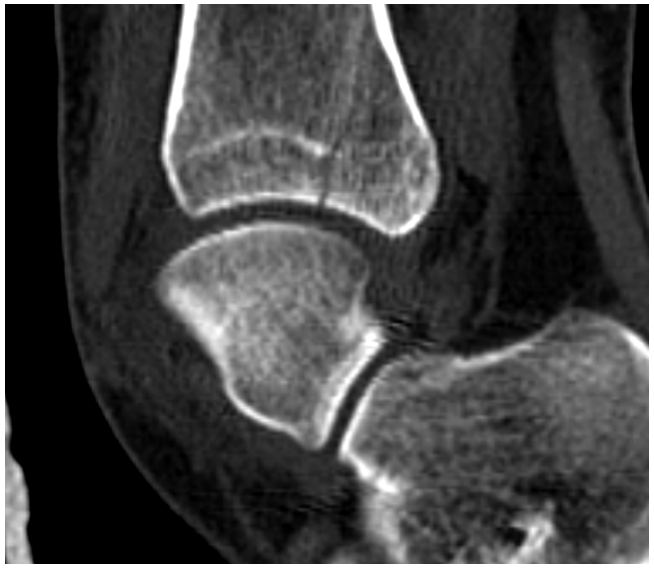

Clin Orthop Relat Res (2008) 466:1692–1698
DOI 10.1007/s11999-008-0224-5

Sreevathsa Boraiah MD, Michael J. Gardner MD,
David L. Helfet MD, Dean G. Lorich MD

High Association of Posterior Malleolus Fractures with Spiral Distal Tibial Fractures

- 37 fractures with spiral fracture pattern
  - 56% associated posterior malleolus fracture

- 62 fractures of the distal third of the tibia diaphysis
  - 39 % associated posterior malleolus fracture

- ***24 % of posterior malleolus fractures were not seen on plain x-rays but only on CT scans***

Clin Orthop Relat Res (2008) 466:1692–1698
DOI 10.1007/s11999-008-0224-5

Sreevathsa Boraiah MD, Michael J. Gardner MD,
David L. Helfet MD, Dean G. Lorich MD

High Association of Posterior Malleolus Fractures with Spiral Distal Tibial Fractures

Table 1. Incidence rates and comparison of fractures before and after protocol

Parameter	Preprotocol (CT scan decided by treating surgeon)	Postprotocol (All CT scan)
Patients with lower third shaft fractures	39	23
Associated posterior malleolus fractures	13 (33%)	11 (48%)
Spiral fractures	19 (49%)	16 (70%)
Low-energy injuries	22 (56%)	16 (70%)
Delayed/missed diagnosis of associated posterior malleolus fracture	2 (5%)	0

- One missed posterior malleolus displaced during mobilisation
- All recognized posterior malleolus fractures treated with internal fixation

J Trauma, 2011

Results of a Computed Tomography Protocol Evaluating Distal Third Tibial Shaft Fractures to Assess Noncontiguous Malleolar Fractures

Gregory J. Purnell, MD, Ericka R. Glass, MD, Daniel T. Altman, MD, Robert L. Sciulli, MD, Matthew T. Muffly, BS, and Gregory T. Altman, MD

67 distal third tibial fractures:

- 29 (43%) intra-articular fracture:
  - 17 screw fixation
  - 29 splinted and non-weight-bearing

No follow-up

2012: The Nordic Nuclear Safety Research raised concern about the increased use of CT scan in Nordic countries

”kun at anvende CT, hvor der foreligger et relevant klinisk spørgsmål, hvor udfaldet af den kliniske problemstilling afhænger af CT-undersøgelsen”

Does preoperative CT scanning of tibial diaphyseal fractures below isthmus change fracture treatment ?

- Retrospective study, Aalborg Univesity Hospital

- Inclusion criteria:
  - *Tibial diaphyseal fracture below the isthmus in a skeletally mature adult*
  - Preoperative X-ray ***and*** CT of the tibia

- Exclusion criteria:
  - Pilon fracture

Nekrasas et al. NOF 2012

Intra-articular fractures in 27 out of 34 included tibial fractures

AO -type	Numbers	
	X-ray	CT
43-B	**13**	**15**
43-C	**5**	**12**
SUM	18	27

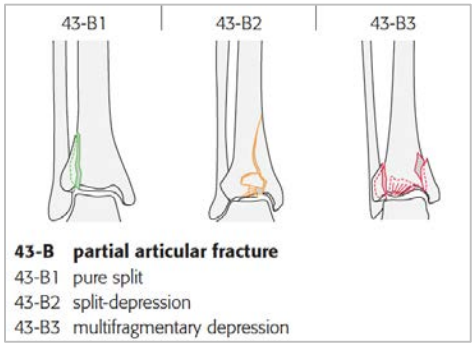

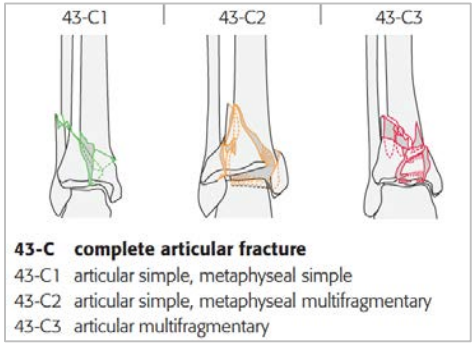

- 9 of 27 intraarticular fractures only visible on CT
- *5 of the 9 occult intraarticular fractures had additional screw fixation*
- *Preoperative CT led to change in surgery in 5 out of 34 cases*

Nekrasas et al. NOF 2012

Are all intra-articular fractures detected with CT ?

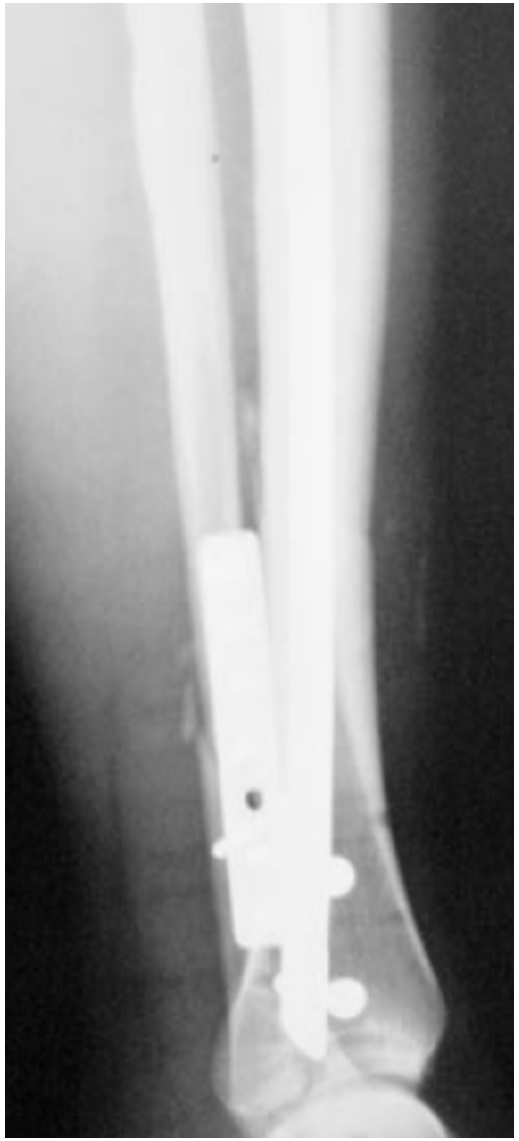

Hou et al., J Trauma, 2009

The Journal of TRAUMA® Injury, Infection, and Critical Care

A Occult and Regular Combination Injury: The Posterior Malleolar Fracture Associated With Spiral Tibial Shaft Fracture

Zhiyong Hou, Qi Zhang, Yingze Zhang, PhD, Shiling Li, Jinshe Pan, and Haotian Wu

34 tibial shaft *spiral* fractures

- X-ray: 3 posterior malleolar fractures
- CT: 24 posterior malleolar fractures
- MRI: 3 posterior malleolar fractures

Combined tibial fracture and posterior malleolar fracture: 30/34 (88%)

Arch Orthop Trauma Surg (2014) 134:1661–1666
DOI 10.1007/s00402-014-2095-4

Stephen J. Warner · Patrick C. Schottel · Matthew R. Garner · David L. Helfet · Dean G. Lorich

Ankle injuries in distal tibial spiral shaft fractures: results from an institutional change in imaging protocol

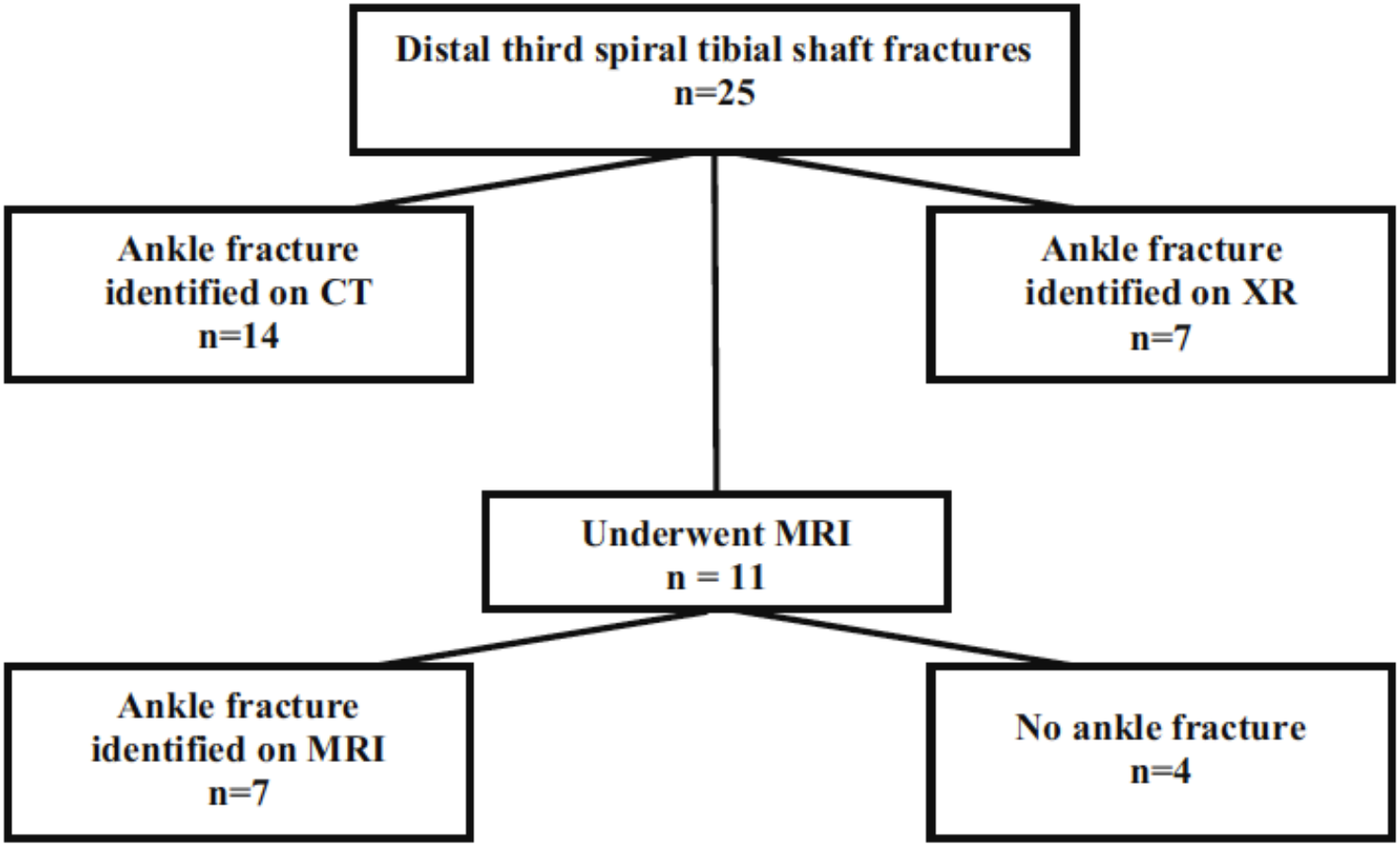

Arch Orthop Trauma Surg (2014) 134:1661–1666
DOI 10.1007/s00402-014-2095-4

Stephen J. Warner · Patrick C. Schottel · Matthew R. Garner · David L. Helfet · Dean G. Lorich

Ankle injuries in distal tibial spiral shaft fractures: results from an institutional change in imaging protocol

Distal third spiral tibial shaft fractures

n=7

n=4

Combined tibial fracture and ankle fracture: 21/25 (84%)

71% fixation of ankle fracture

100% of ankle fractures: restricted post-operative weightbearing

CT in preoperative planning

- Nail or frame ? (or plate ?)
- Additional screw ?
- Reduction ?

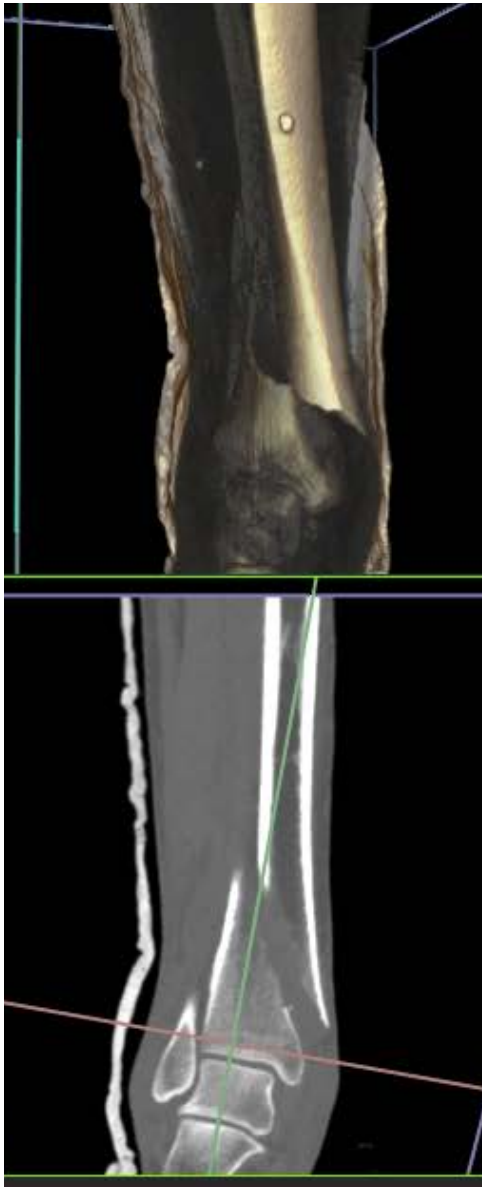

- Exact fracture reduction
- Olive drop-wire, good stability
- No foot frame

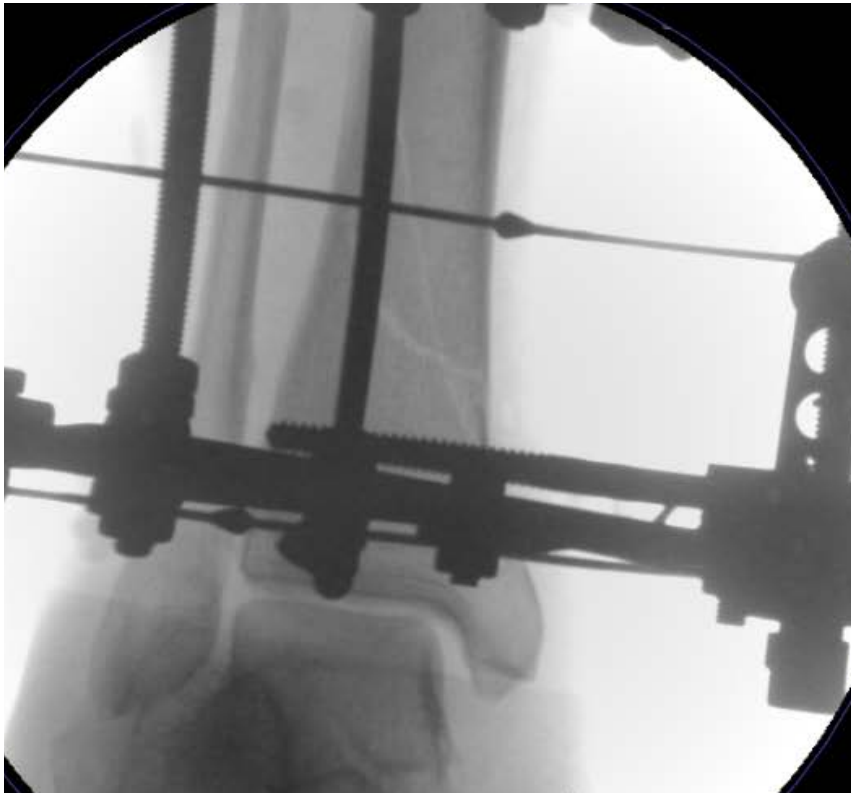



Nail or frame ?

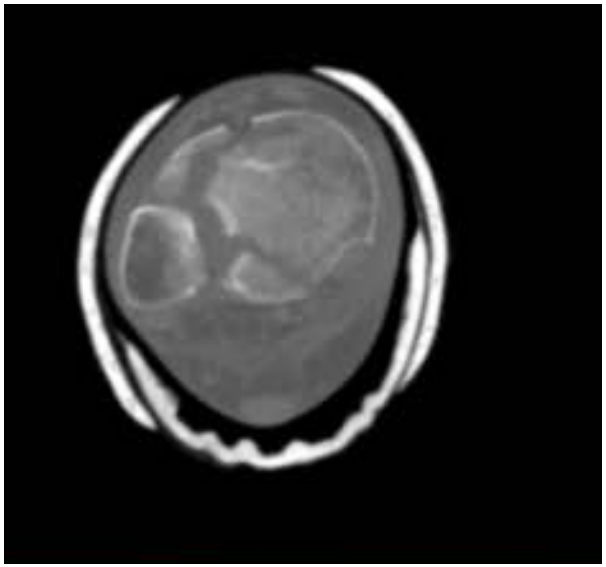

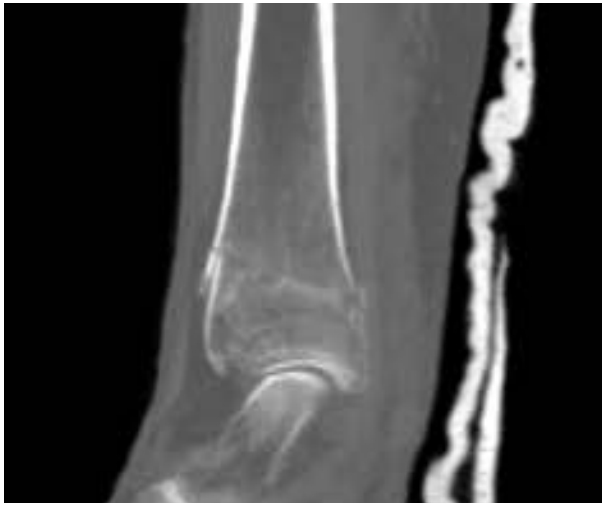

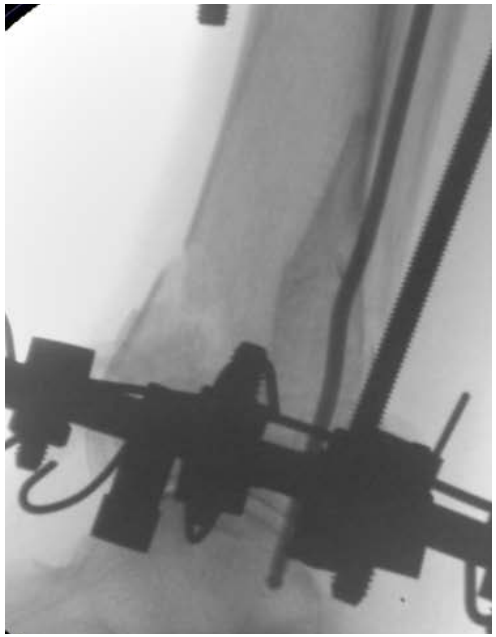

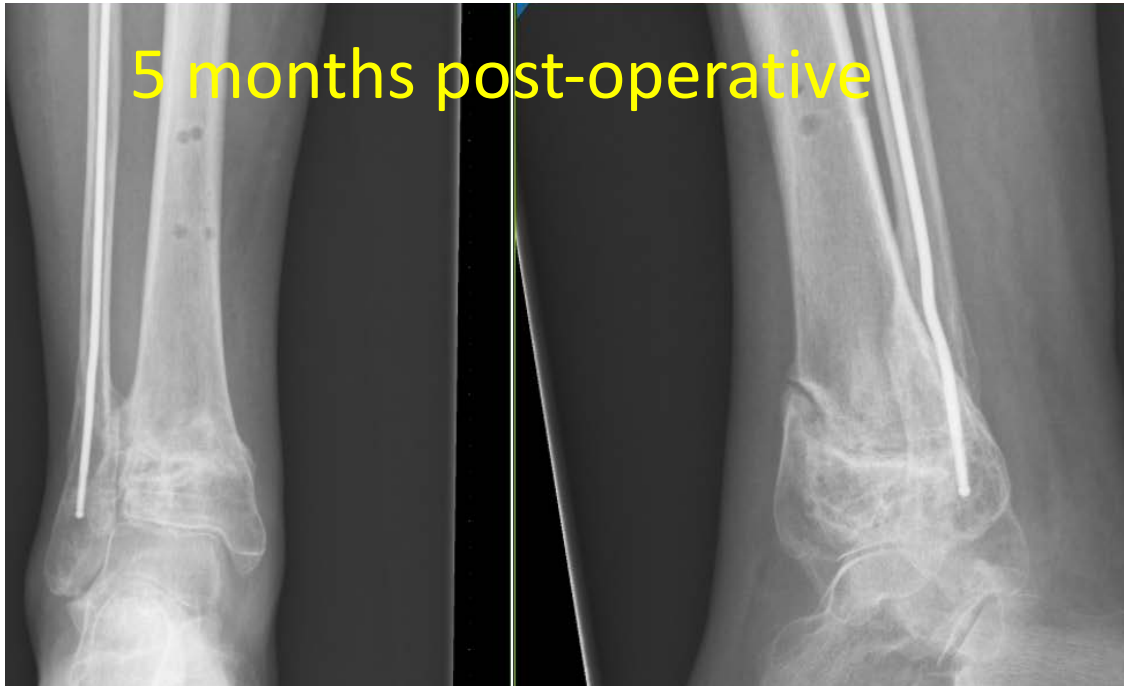
5 months post-operative

Journal of Bone and Joint Surgery - British Volume, Vol 87-B, Issue 5, 692-697.
doi: 10.1302/0301-620X.87B5.15982

Anatomy of pilon fractures of the distal tibia

C. J. Topliss, FRCS, Specialist Registrar; M. Jackson, FRCS (Tr & Orth), Consultant Senior Lecturer; and R. M. Atkins, DM, FRCS, Consultant Reader

University Department of Orthopaedic Surgery, Level 5, Bristol Royal Infirmary, Bristol BS2 8HW, UK.

CT.

Fracture fragments.

Articular CT scans were available in 108 of the 126 fractures. Six distinct fragments could be recognised although not all were universally present. The major fragments were anterior, posterior, medial, anterolateral, posterolateral (Fig. 5) and die-punch (Fig. 6).

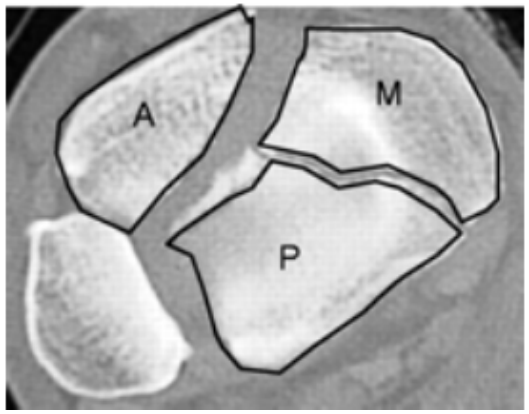

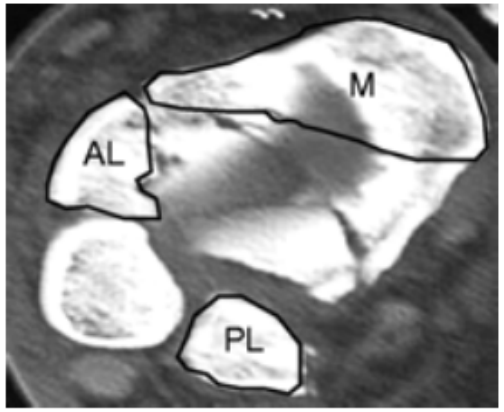

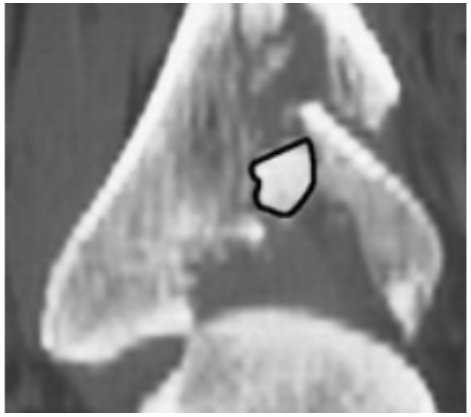

Two fracture families: 33% sagittal split; 56% coronal split

CT: ***Iatrogenic risk of cancer ?***

The NEW ENGLAND JOURNAL of MEDICINE

REVIEW ARTICLE
CURRENT CONCEPTS

Computed Tomography — An Increasing Source of Radiation Exposure

David J. Brenner, Ph.D., D.Sc., and Eric J. Hall, D.Phil., D.Sc.

N Engl J Med 2007; 357:2277-2284 | November 29, 2007 | DOI: 10.1056/NEJMra072149

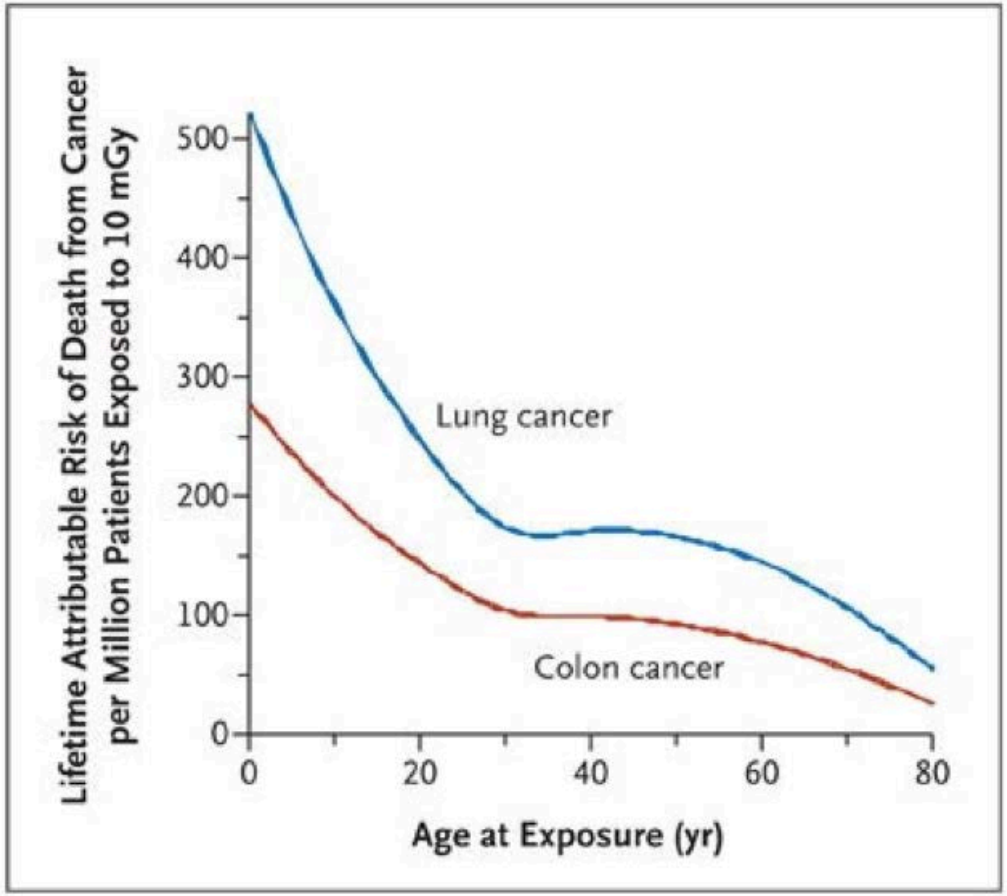

Subjecting Radiologic Imaging to the Linear No-Threshold Hypothesis: A Non Sequitur of Non-Trivial Proportion

Jeffry A. Siegel[1], Charles W. Pennington[2], and Bill Sacks[3]

[1]Nuclear Physics Enterprises, Marlton, New Jersey; [2]NAC International (retired), Norcross, Georgia, and executive nuclear energy consultant, Alpharetta, Georgia; and [3]U.S. Food and Drug Administration (retired), Green Valley, Arizona

The Journal of Nuclear Medicine Vol 58, Jan 2017. (impact factor: 5.8)

Non sequitor: an invalid argument where the conclusion could be either true or false.

Non-existing evidence of imaging-related (particulary CT/PET-CT) carcinogenic risk.

Radiophobia centered and not scientifc approach has led to the guidelines of “as low as reasonable achievable doses”.

Iatrogenic risk of cancer

- Background radiation dose in DK: 4 mSv/year

- Tibial CT scan (80 kV, 30mAs):
  - effective radiation dose: 0.03 mSv
  - About 50 hours additional background radiation
  - Additional risk of death due to cancer increases 0.0001%
  - Risk of death due to cancer increases from 30% to 30.0001%

Why preoperative CT ?

- Occult intra-articular fracture ?
  - Risk of displacement during
    - Nailing
    - Postoperative mobilisation

- Preoperative planning:
  - Nail / (plate) / Ring fixation
  - Reduction, key-fragment

Why not preoperative CT ?

- Iatrogenic risk of cancer ??
  - Small, questionable