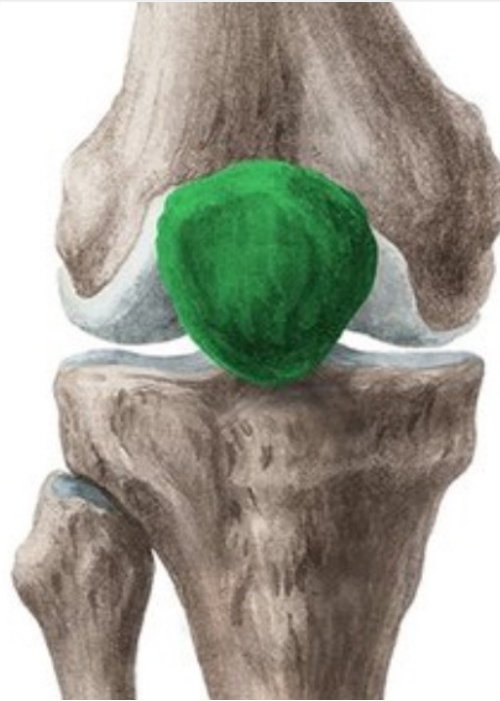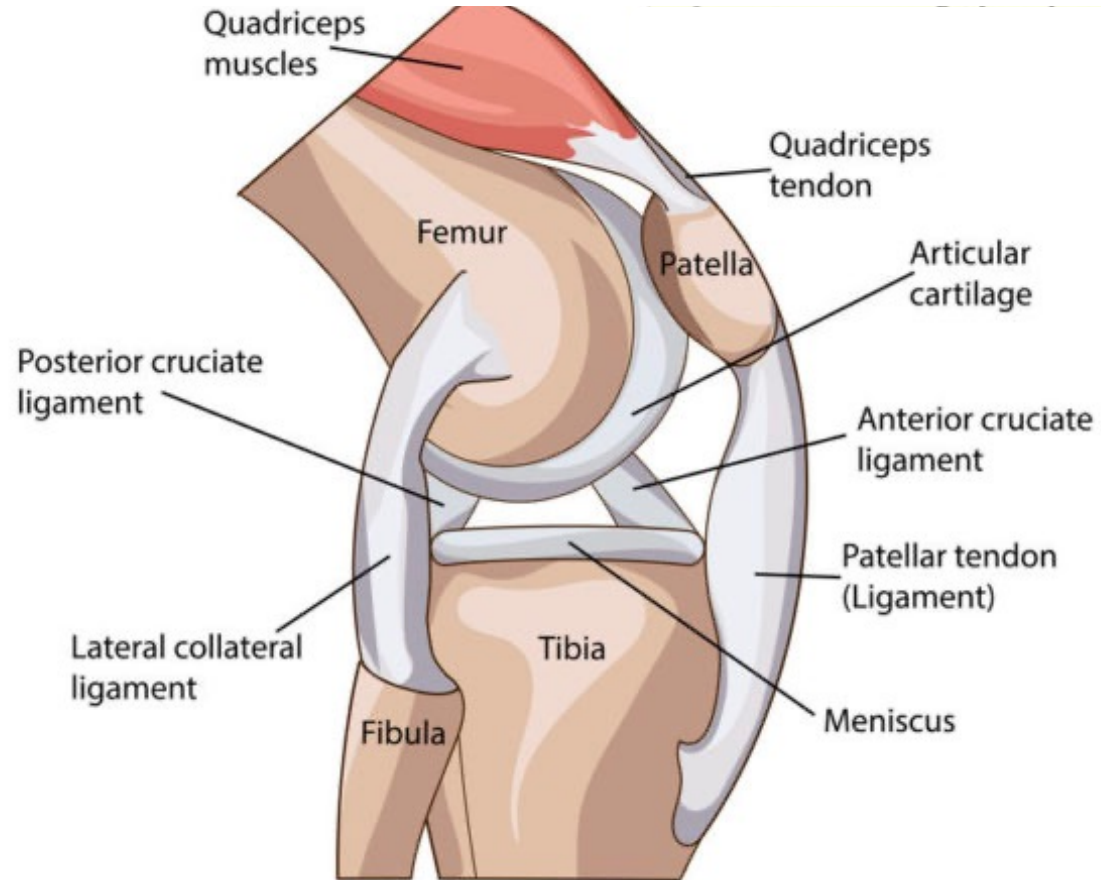




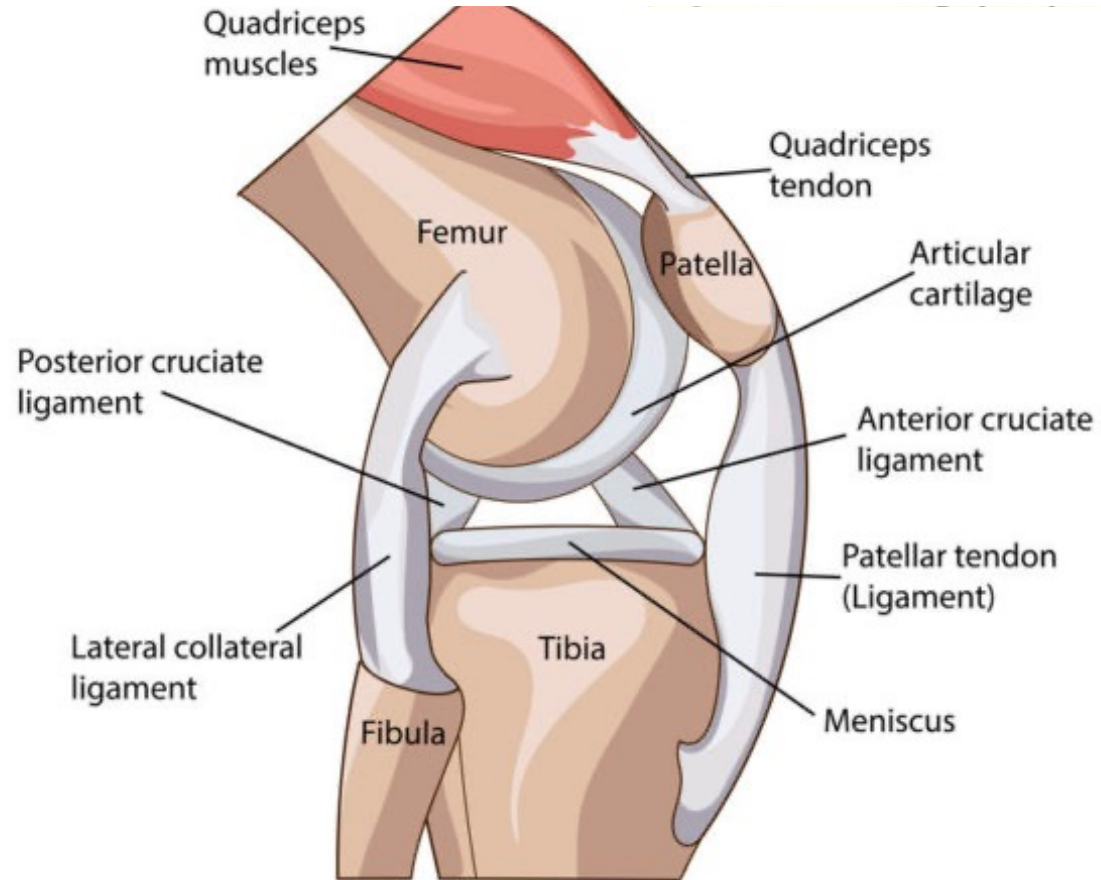
Det basale

Funktionel anatomi, klassifikation, diagnostik , epidemiologi

- Største sesamknogle i kroppen
- Indlejret i quadricepssenen
- Apex patella eneste uden brusks



- Største sesamknogle i kroppen
- Indlejret i quadricepssenen
- Apex patella eneste uden brus



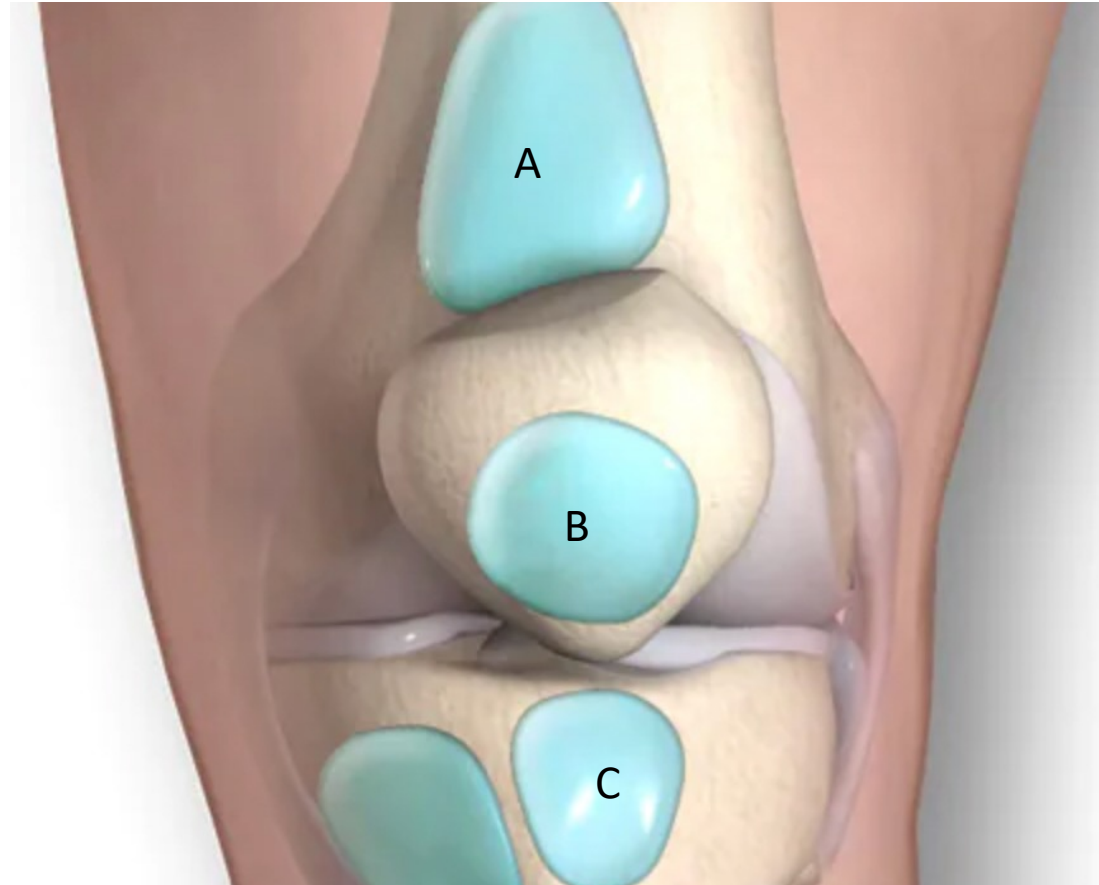
- **Bevar Apex¹⁻²**

¹ Howatt J et al., Patellar Fractures Anatomy, Mechanics and Surgical management, J Bone Joint Surg Am 2021;103;2237-46

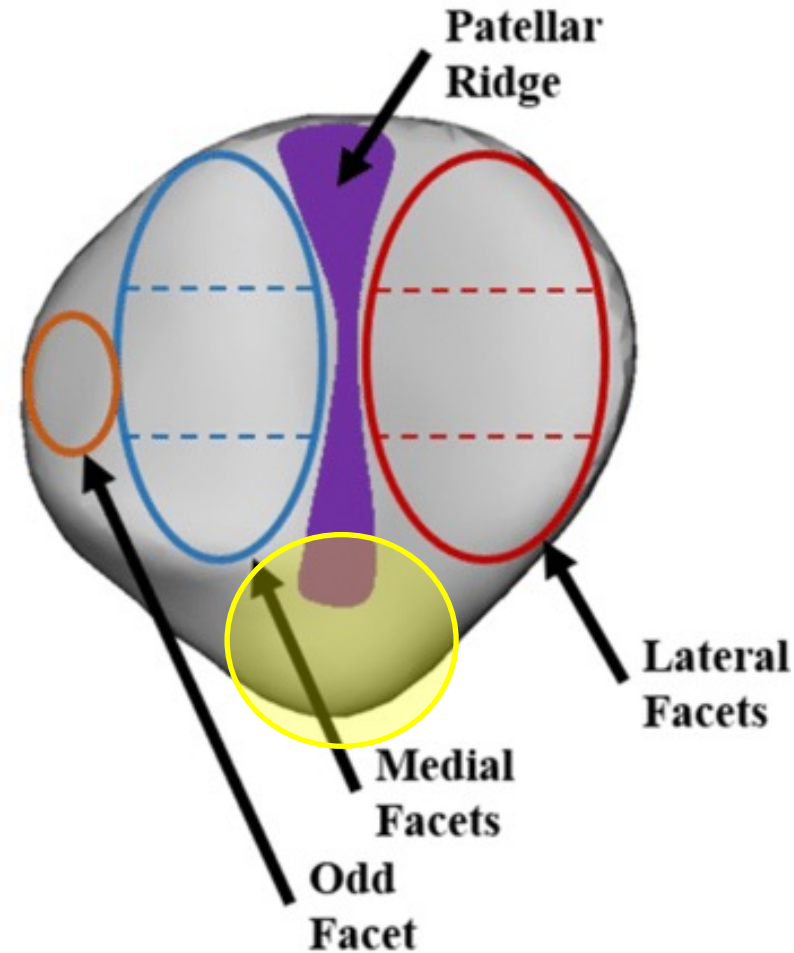
² Böstman O et al. Comminuted displaced fractures of the patella, Injury 1981;13(3);196-202

De tre væsentligste bursa:

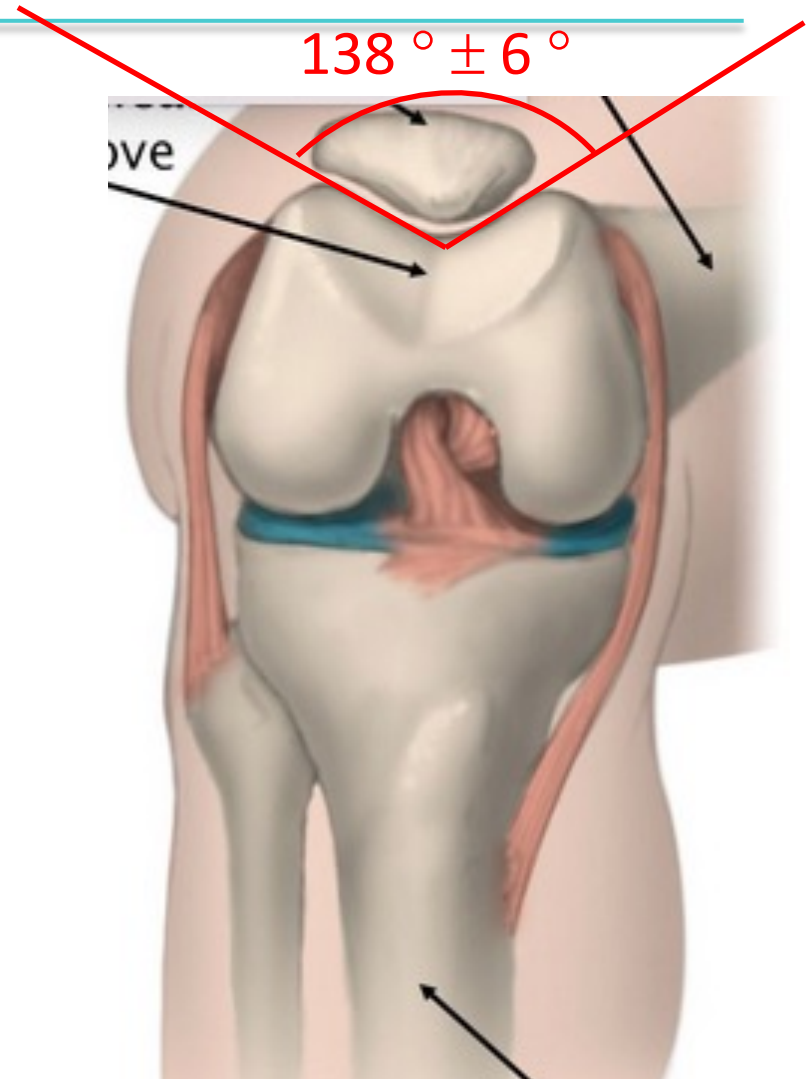
- Suprapatellare (A)
- Præpatellare (B)
- Infrapatellare (C)



- Hele patella er bruskdækket (- Apex)
- Det tykkeste bruske i kroppen
- 2 Facetter adskilt af en knoglekam (facies articularis)

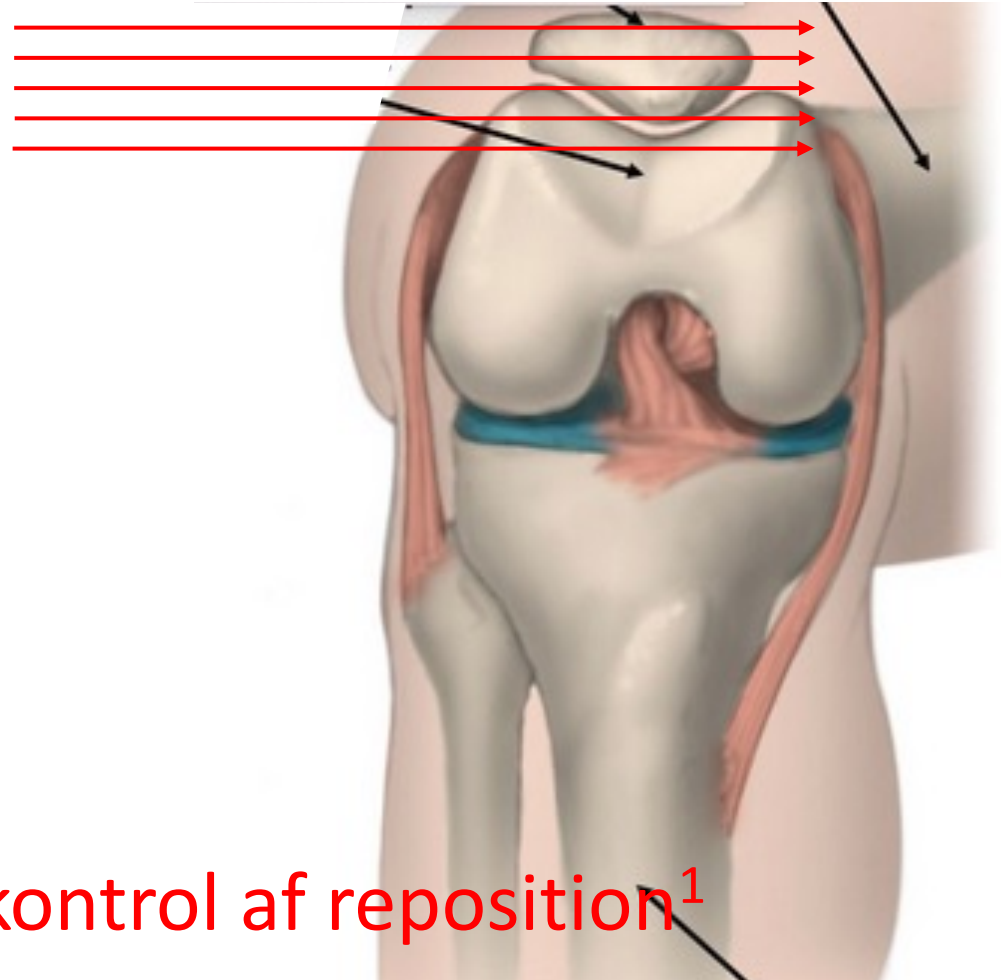


Patellafemorale led



³ Grelsamer RP et al., The biomechanics of the patellofemoral joint. J Orthop Sports Phys Ther. 1998;28(5):286-298.

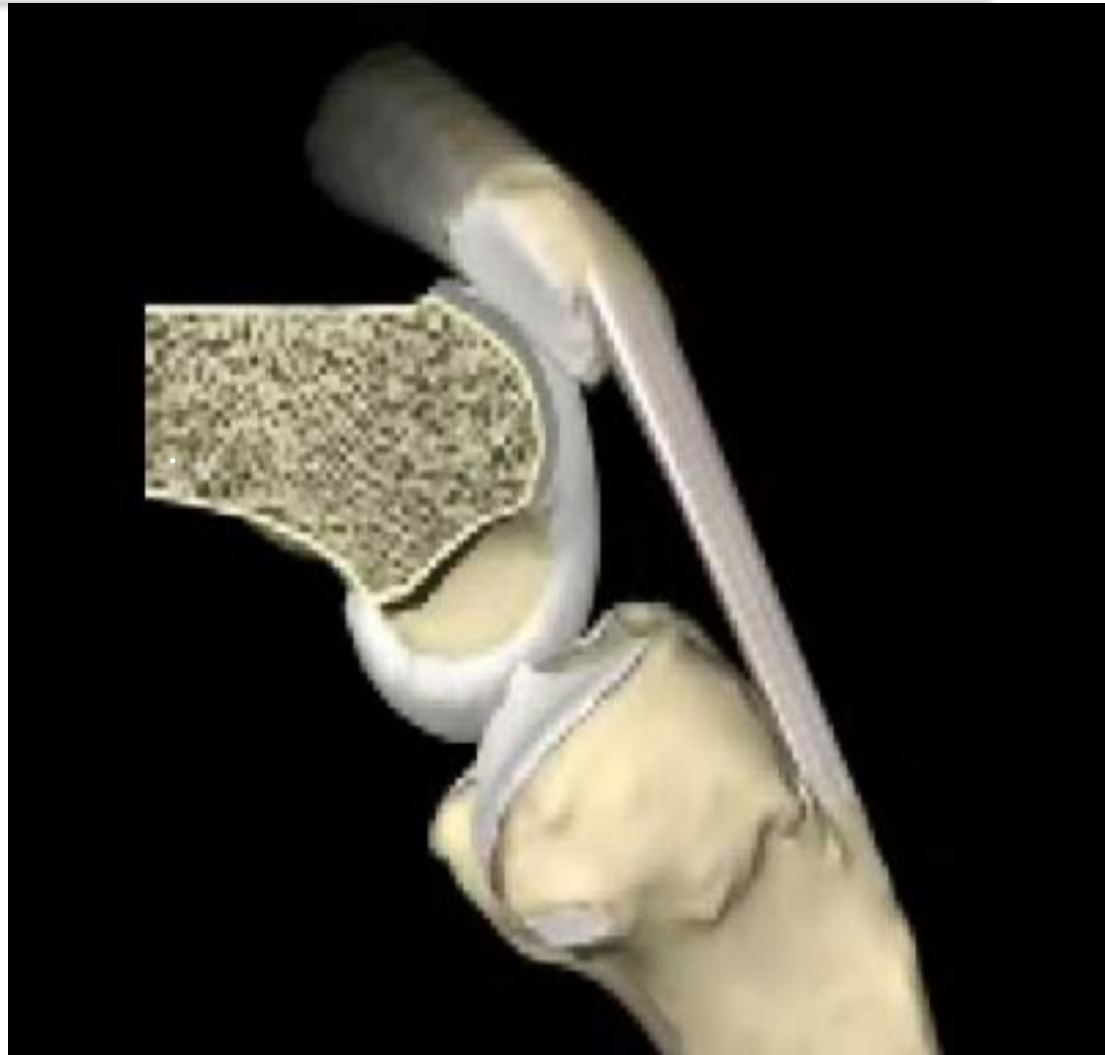Røntgen strålegang



Visuel eller manuel kontrol af reposition¹

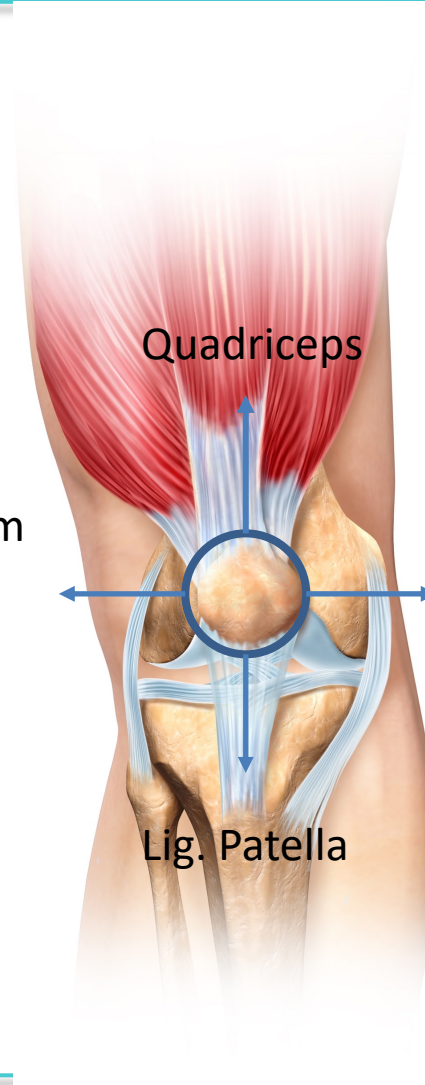
¹ Howatt J et al., Patellar Fractures Anatomy, Mechanics and Surgical management, J Bone Joint Surg Am 2021;103;2237-46

- Ekstension af knæled
- Højt tryk på patella v. 40- 45 gr.



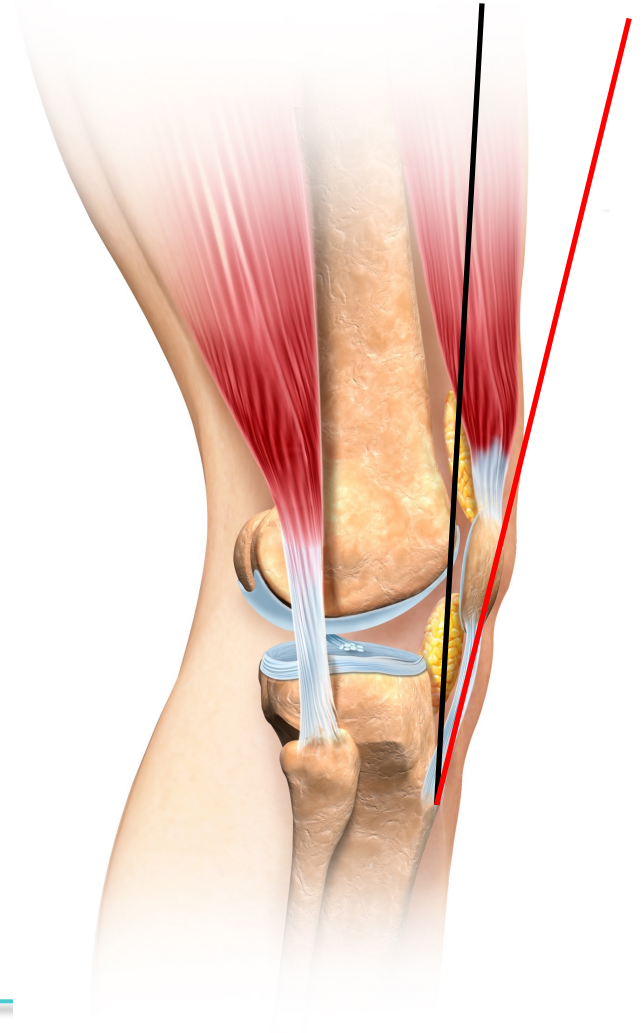
Kraftpåvirkning og begrænsninger
på patella under brug

Lat. retinaculum
Vastus lateralis
LPFL
Trac. iliotibiale



Med. retinaculum
Vastus med.
MFPL

Patella øger momentarmen for quadriceps
-> Øget kraft ved ekstension



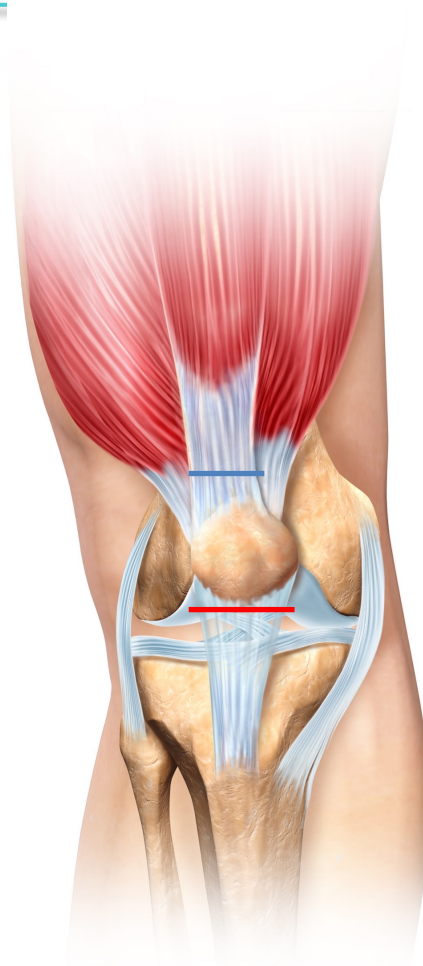
Ruptur af patellasene

Ruptur af quadricepssene

- Patella Baja (Patella står lavere på rgt)

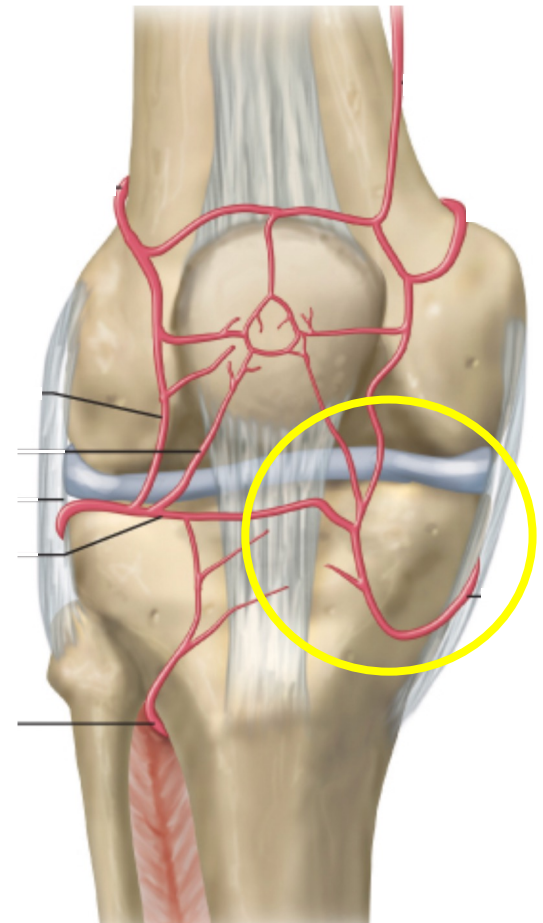
Ruptur af patellasenen

- Patella Alta (Patella står højere på rgt.)



Patellas blodforsyning³:

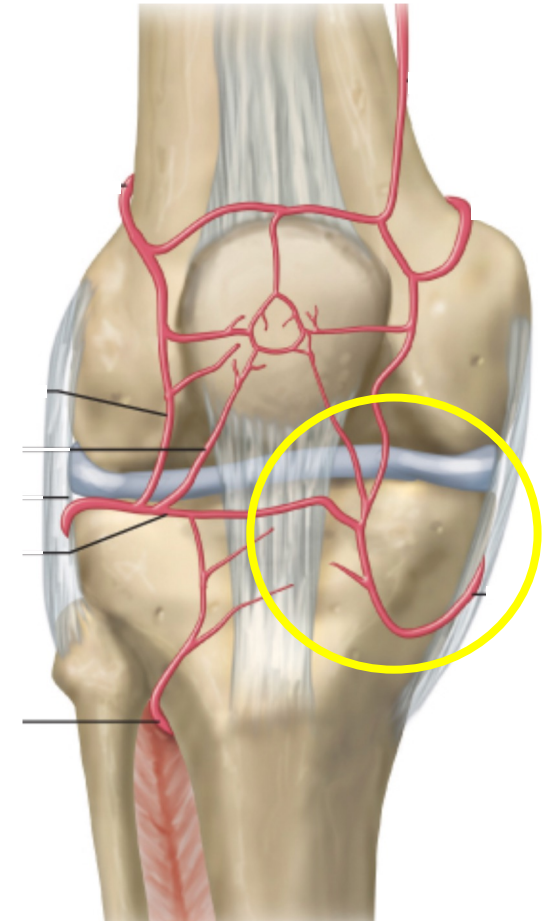
Hovedparten af blodforsyning fra nedre mediale kant



³ Nicholls RL et al., Intraosseous blood flow disturbance during a medial or lateral arthrotomy in total knee arthroplasty: a laser Doppler flowmetry study. Knee Surg Sport Traumatol Arthrosc. 2006;14(5);411-6

Patellas blodforsyning:

Hovedparten af blodforsyning fra nedre mediale kant



Undgå inferomedial artrotomi³

³ Nicholls RL et al., Intraosseous blood flow disturbance during a medial or lateral arthrotomy in total knee arthroplasty: a laser Doppler flowmetry study. Knee Surg Sport Traumatol Arthrosc. 2006;14(5);411-6

Hovedregler:

- Excentrisk belastninger giver tværfrakturer
- Direkte traume mod patella giver komminutte frakturer

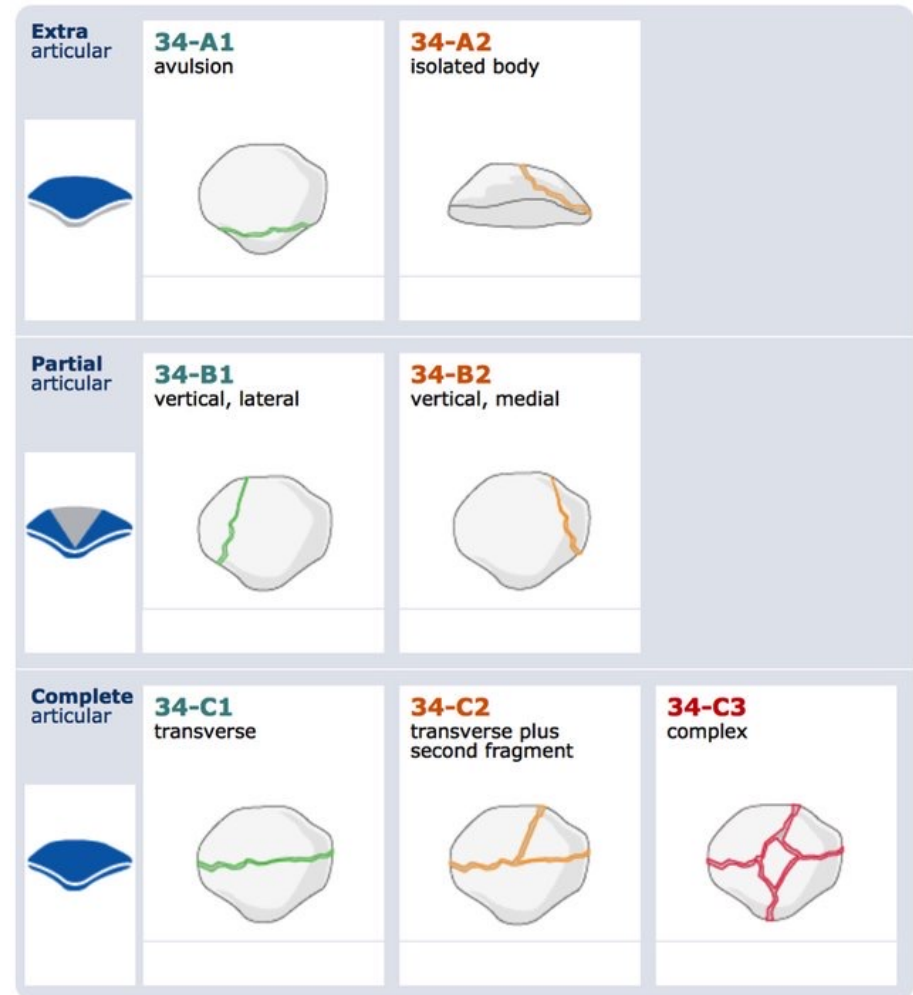

AO klassifikation 34-?

- Delt op i:
 - (A) Ekstraartikulære
 - (B) Delvist artikulære
 - (C) Komplet artikulære

- Komplette frakturer:
 - Opdeles efter kompleksitet

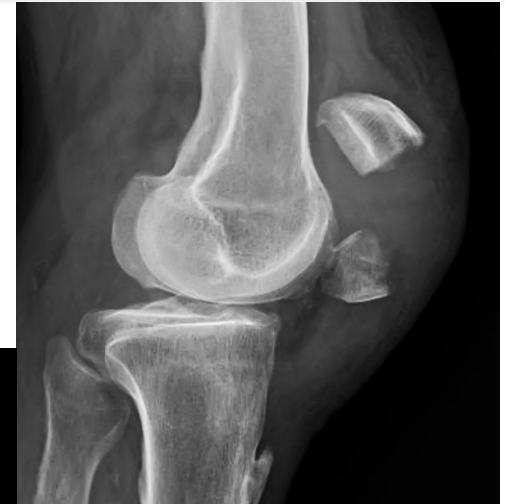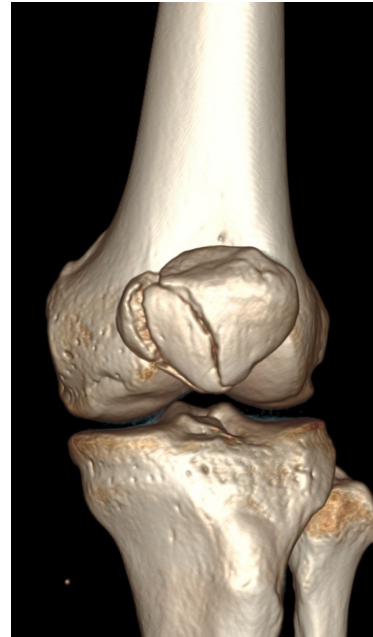- Moderat reliabilitet⁴
(Rgt: R=0,40 CT: R= 0,54)



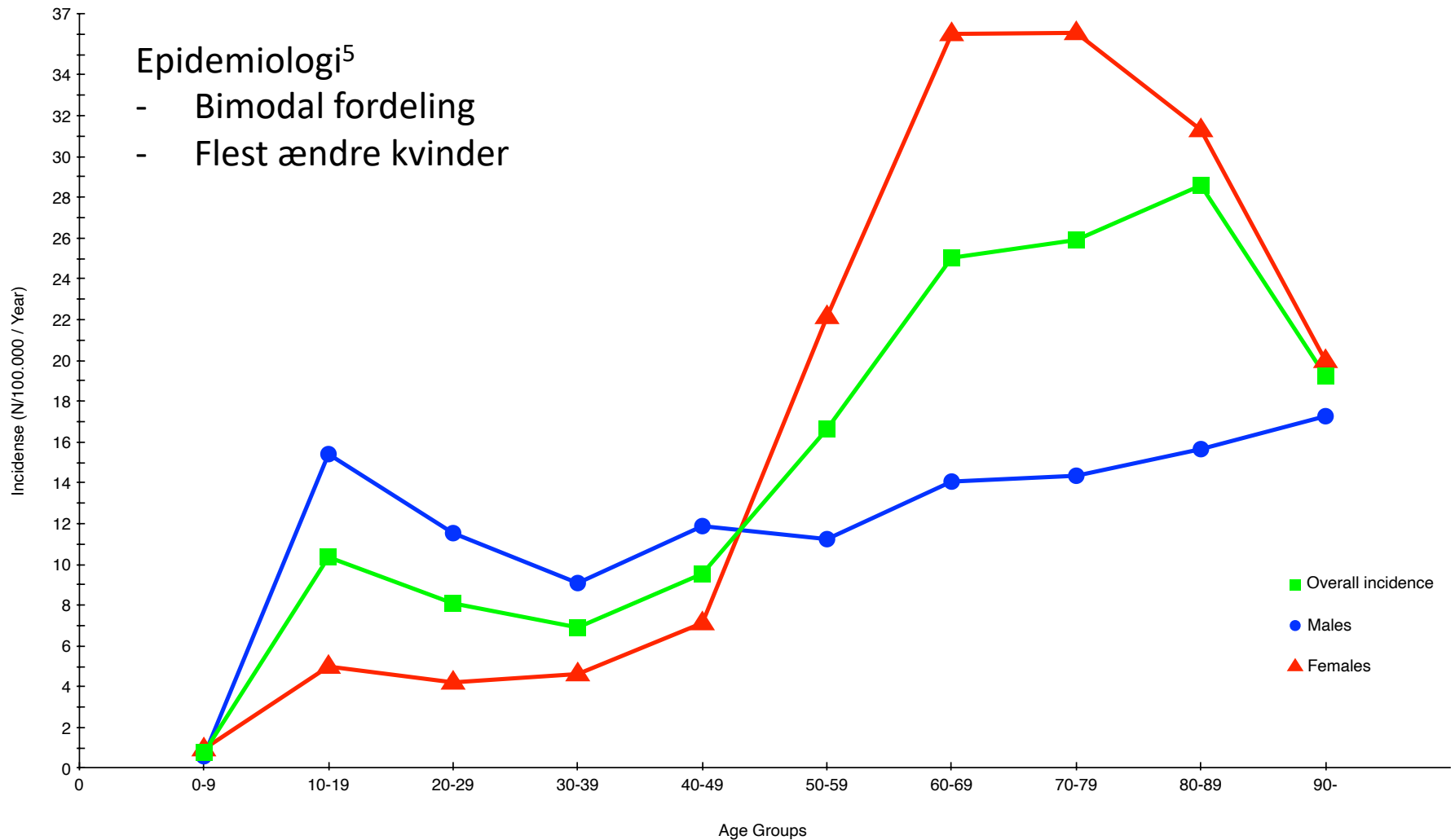
⁴ Seon-Eun Bryun et. al, Application of Three-Dimensional Computed Tomography Improved the Interrater Reliability of the AO/OTA Classification Decision in a Patellar Fracture, J Clin. Med. 2021;10(15);3256

Diagnostik:

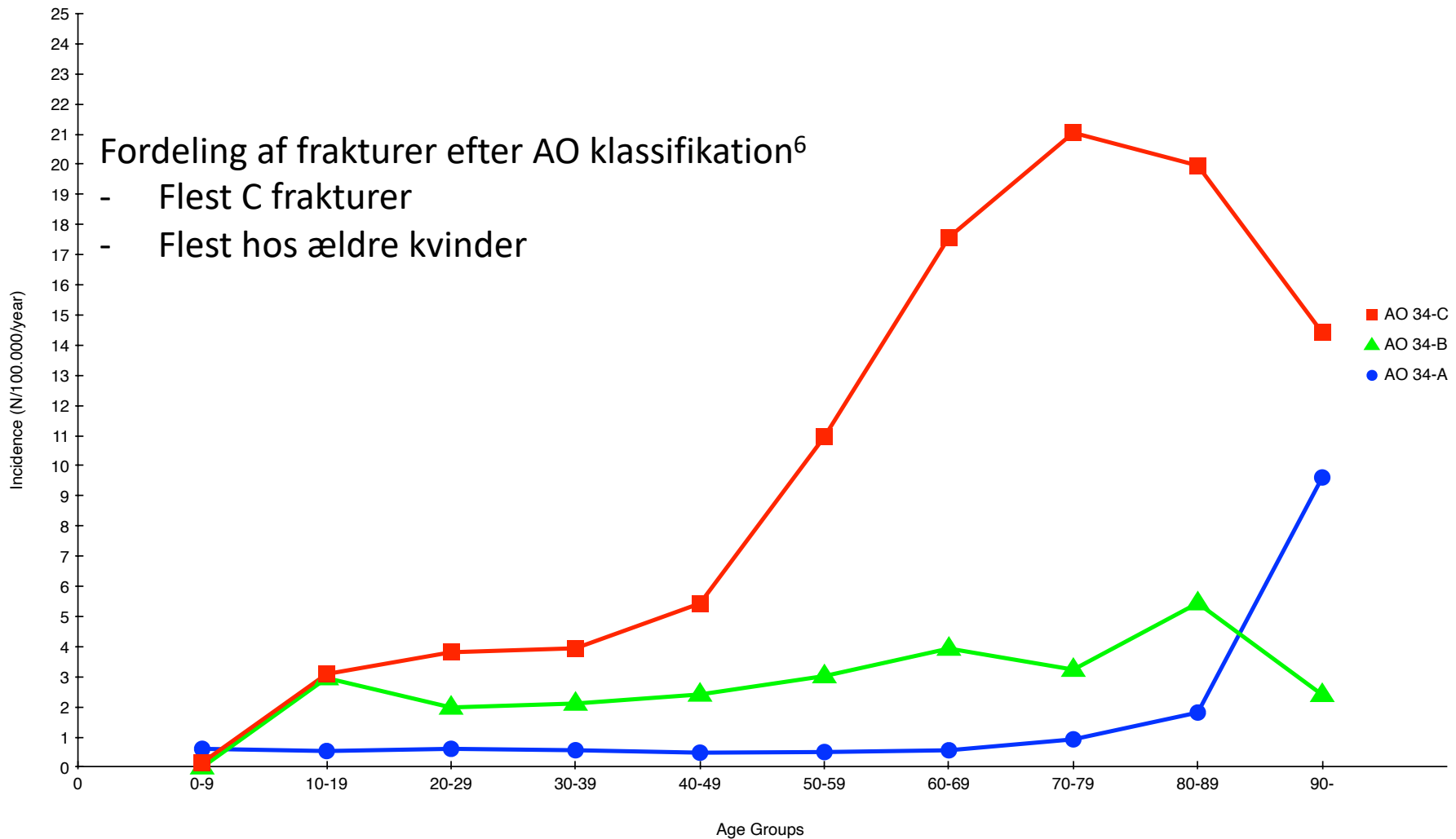
- Objektiv undersøgelse:
 - Anamnese
 - Objektivt (hæmartron, bevægelse)
- Diagnostik¹:
 - Røntgen (ikke skyline !)
 - CT skanning



¹ Howatt J et al., Patellar Fractures Anatomy, Mechanics and Surgical management, J Bone Joint Surg Am 2021;103;2237-46



⁵ Larsen P et al., Incidence and epidemiology of patellar fractures, Orthopaedics, 2016;39(6)



⁵ Larsen P et al., Incidence and epidemiology of patellar fractures, Orthopaedics, 2016;39(6)

	High energy	Low energy	Missing	Falls from > 3 m	Falls from > 1 m, but < 3m	Fall	RTA	Sport	Direct blows	Missing
34-A	15	116	1	0	3	73	15	25	10	6
34-B	24	124	1	0	8	94	24	11	7	5
34-C	65	410		4	15	352	65	18	10	11
Total	108 (14%)	646 (86%)	2	4 (1%)	26 (3%)	519 (69%)	104 (14%)	54 (7%)	27 (4%)	20 (3%)
Males										
34-A	9	56		0	2	29	9	18	4	3
34-B	18	74	1	0	5	53	18	7	6	4
34-C	50	123		4	9	95	46	11	2	6
Total	77 (23%)	253 (76%)	1	4 (1%)	16 (5%)	177 (54%)	73 (22%)	36 (11%)	12 (4%)	12 (4%)
Females										
34-A	6	60		0	1	44	6	7	6	2
34-B	6	50		0	3	41	6	4	1	1
34-C	19	283	1	0	6	257	19	7	8	6
Total	31 (7.3%)	393 (92.5%)	1	0 (0%)	10 (2%)	342 (81%)	31 (7%)	18 (4%)	15 (4%)	8 (2%)

⁵ Larsen P et al., Incidence and epidemiology of patellar fractures, Orthopaedics, 2016;39(6)

- CT skanning er en fordel til præoperativ planlægning
 - Peroperativ røntgen sikre ikke reposition af frakturen (palpation/inspektion)
 - Bevar apex hvis muligt (bedre outcome – mindre artrose)
 - Undgå inferomedial artrotomi (bevarer blodforsyning)
 - Vi behandler hovedsageligt ældre kvinder med komplekse frakturer
-